

**Micro-ultrasound for the detection of clinically significant prostate cancer in biopsy-naive men with negative MRI**

Patrick Albers<sup>1</sup>, Jacob Bennett<sup>1</sup>, Moira Evans<sup>1</sup>, Ella St. Martin<sup>1</sup>, Betty Wang<sup>1</sup>, Stacey Broomfield<sup>1</sup>, Anaïs Medina Martín<sup>2</sup>, Wendy Tu<sup>3</sup>, Christopher Fung,<sup>3</sup> Adam Kinnaird<sup>1,2,4,5,6</sup>

<sup>1</sup>Division of Urology, Department of Surgery, University of Alberta, Edmonton, AB, Canada; <sup>2</sup>Alberta Prostate Cancer Research Initiative (APCaRI), Edmonton, AB, Canada; <sup>3</sup>Department of Radiology & Diagnostic Imaging, University of Alberta, Edmonton, AB, Canada; <sup>4</sup>Cancer Research Institute of Northern Alberta (CRINA), Edmonton, AB, Canada; <sup>5</sup>Alberta Centre for Urologic Research and Excellence (ACURE), Edmonton, AB, Canada; <sup>6</sup>Department of Oncology, University of Alberta, Edmonton, AB, Canada

*Funding: Alberta Cancer Foundation, Bird Dogs, University Hospital Foundation*

**Cite as:** Albers P, Bennett J, Evans M, et al. Micro-ultrasound for the detection of clinically significant prostate cancer in biopsy-naive men with negative MRI. *Can Urol Assoc J* 2024 April 2; Epub ahead of print. <http://dx.doi.org/10.5489/cuaj.8626>

Published online April 2, 2024

**Corresponding author:** Dr. Adam Kinnaird, Division of Urology, Department of Surgery, University of Alberta, Edmonton, AB, Canada; [ask@ualberta.ca](mailto:ask@ualberta.ca)

\*\*\*

**ABSTRACT**

**Introduction:** Despite a negative magnetic resonance imaging (MRI), some patients may still harbor clinically significant prostate cancer (csPCa, Gleason grade group  $\geq 2$ ). High-resolution micro-ultrasound (microUS) is a novel imaging technology that could visualize csPCa that is missed by MRI.

**Methods:** This retrospective review included 1011 consecutive patients biopsied between September 2021 and July 2023 in Alberta,

Canada. Among them were 103 biopsy-naive patients with negative MRI (Prostate Imaging Reporting & Data System [PI-RADS]  $\leq 2$ ) undergoing microUS-informed prostate biopsy (n=56) scored using Prostate Risk Identification Using Micro-ultrasound (PRI-MUS) or standard

**KEY MESSAGES**

- A negative MRI can miss 15% or more of clinically significant prostate cancers.
- Patients with PRI-MUS  $\geq 3$  and negative MRI had clinically significant prostate cancer detected at a rate of 42%.
- Micro-ultrasound can improve the detection rate of clinically significant prostate cancers for patients with negative MRI.

transrectal ultrasound prostate biopsy (n=47). The primary outcome was detection rate of csPCa stratified by biopsy technique and PRI-MUS score.

**Results:** MicroUS biopsy identified csPCa in 14/56 (25%) compared to standard biopsy in 8/47 (17%) (p=0.33). Patients with lesions PRI-MUS  $\geq 3$  had csPCa detected at a higher rate compared to patients with PRI-MUS  $\leq 2$  (42% vs. 16%, p=0.03). The csPCa detection rate was significantly different comparing patients with PSA density  $< 0.15$  and PRI-MUS  $\leq 2$  compared to patients with PSA density  $\geq 0.15$  and PRI-MUS  $\geq 3$  (14% vs. 60%, p=0.02).

**Conclusions:** MicroUS may aid in the detection of csPCa for patients with negative MRI.

## INTRODUCTION

New imaging technologies such as multiparametric magnetic resonance imaging (MRI) have improved our ability to detect and characterize prostate cancer lesions<sup>1,2</sup>. The current Canadian Urologic Association and European Association of Urology guidelines recommend that for biopsy naïve men with a negative MRI (PI-RADS score  $\leq 2$ ), prostate biopsy can be avoided for low risk men<sup>3,4</sup>. Despite the improvements afforded by MRI, it can miss 15% or more of clinically significant prostate cancer (csPCa), defined as Gleason grade group  $\geq 2$ <sup>5</sup>.

To address this diagnostic gap, high resolution micro-ultrasound (microUS) can be utilized. MicroUS is an advancement from traditional ultrasound methods and offers the ability to visualize prostate tissue with more detail, leading to improved identification and localization of suspicious lesions<sup>6-9</sup>. MicroUS has a higher frequency of ultrasound waves at 29 MHz, compared to standard ultrasound in the 6 MHz range, allowing differentiation of minute structural variations within the prostate<sup>10</sup>. MicroUS employs the Prostate Risk Identification using Micro-Ultrasound (PRI-MUS) scoring system, which, like the PI-RADS scoring system, employs a Likert scale ranging from 1 to 5. Lesions rated  $\geq 3$  on this scale are indicative of a heightened risk for prostate cancer<sup>11</sup>. Exact Imaging has developed a formal training course for novice urologists seeking to implement this technology in their practice<sup>12</sup>.

The primary objective of this study is to determine the benefit of utilizing microUS informed prostate biopsy for patients with negative MRI for the detection of csPCa.

## METHODS

This retrospective review was performed looking at 1011 consecutive patients biopsied by a single urologist between September 2021 and July 2023 at a single center in Alberta, Canada. In total there were 103 biopsy naïve patients with clinical suspicion of prostate cancer who underwent a prostate biopsy with negative MRI. 56 patients underwent combined MRI/microUS-guided transrectal biopsy using the ExactVu MRI/microUS fusion device (Exact Imaging, Markham, Canada) scored at the time of biopsy by the urologist using the PRI-MUS protocol. The urologist has completed the formal microUS mastery course provided by Exact Imaging. A further 47 underwent standard transrectal ultrasound (TRUS) guided biopsy. Pre-biopsy MRI

was scored using Prostate Imaging Reporting & Data System version 2.1 (PI-RADS) score, and a score of  $\leq 2$  was considered negative. All patients underwent a 12-core systematic transrectal prostate biopsy, with additional targeted cores taken from any prostate lesions scored PRI-MUS  $\geq 3$ . Human research ethics approval was obtained (HREBA.CC-21-0388).

Baseline patient characteristics, including age, ethnicity, family history of prostate cancer, PSA, prostate volume, DRE and PSA density were determined using retrospective chart review of our provincial electronic health records system. Mean values and standard deviations are reported for continuous variables and categorical variables are reported as frequencies (%). The primary outcome was the detection of csPCa between the two groups. Statistical analyses were performed using Chi square test, Fisher's exact test and student T test where appropriate. A two-sided p-value of  $<0.05$  was considered significant.

## RESULTS

A total of 103 biopsy naïve patients with negative MRI (PI-RADS  $\leq 2$ ) underwent prostate biopsy with 56 undergoing microUS biopsy and 47 undergoing TRUS biopsy. There was no significant difference between the two groups for age, ethnicity, family history of prostate cancer, abnormal DRE, PSA, or Prostate volume (Table 1). Fewer men undergoing microUS had a PSA density  $<0.15$  (54% vs. 83%,  $p<0.01$ )

There was no difference in overall csPCa detection rates between microUS and TRUS biopsies (25% vs. 17%,  $p=0.33$ ) (Figure 1). csPCa was detected at a higher rate in men with PRI-MUS  $\geq 3$  lesions compared to men with PRI-MUS  $\leq 2$  (42% vs. 16%,  $p=0.03$ ). csPCa was detected in 8/19 patients with PRI-MUS  $\geq 3$  lesions, with 5/8 (62.5%) detected by targeted biopsies, and 6/8 (75%) detected by systematic biopsy.

A subgroup analysis was performed stratifying men by PSA density. For PSA density  $<0.15$ , the overall detection rate was 10/69 (14%), with 5/30 (17%) for microUS biopsy, and 5/39 (13%) for standard biopsy. For PSA density  $\geq 0.15$ , the overall detection rate was 12/34 (35%), with 9/26 (35%) for microUS biopsy and 3/8 (38%) for standard biopsy. There was a significant difference between the overall detection rates when stratified by PSA Density (14% vs 35%,  $p=0.02$ ). PRI-MUS  $\leq 2$  had a detection of 3/21 (14%) and 3/16 (19%) and PRI-MUS  $\geq 3$  was 2/9 (22%) and 6/10 (60%) for PSA density  $<0.15$  and  $\geq 0.15$  respectively (Figure 2). The csPCa rate for PSA density of  $<0.15$  and PRI-MUS  $\leq 2$  is significantly different from PSA density  $\geq 0.15$  and PRI-MUS  $\geq 3$  (14% vs. 60%,  $p=0.02$ ).

## DISCUSSION

The present study shows that for patients undergoing prostate biopsy with negative MRI, the rate of detection of csPCa by standard TRUS biopsy was 17% and for microUS informed prostate biopsy was 25%. The rate of detection of csPCa was increased to 42% for patients with a lesion PRI-MUS  $\geq 3$ , compared to a detection rate of 16% for patients with PRI-MUS  $\leq 2$ . There was a significant difference between the rates of csPCa when stratified by PSA density (14% vs 35%). The difference was larger for patients with PSA density  $\geq 0.15$  with 60% of patients with PRI-

MUS  $\geq 3$  detecting csPCa compared to 19% for PRI-MUS  $\leq 2$  which is similar to the rates of csPCa detected with PSA density  $< 0.15$ . MicroUS did not have as large of an effect for patients with PSA density  $< 0.15$ , with 14% csPCa detection for PRIMUS  $\leq 2$  compared to 22% for PRIMUS  $\geq 3$ .

A recent study by Avolio et al. found similar rates of clinically significant prostate cancer for patients with negative MRI undergoing microUS informed prostate biopsy at 27% (34/125) compared to 25% (14/56)<sup>13</sup>. Their results showed a lower rate of negative microUS in their study population when compared to this study at 22% (28/125) compared with this study showing 66% (37/56) having PRI-MUS  $\leq 2$ . They further show lower rates of csPCa for negative microUS at 3.6% (1/28) when compared to this study showing 16% (6/37). This could be partially explained by differences in baseline characteristics such as PSA density, though would need further trials to elicit the true rates.

The current CUA and EAU guidelines recommend that for negative MRI, a biopsy can be omitted for low-risk patients. This study found that even for PSA density of  $< 0.15$ , 17% and 13% of patients were diagnosed with csPCa and would have had their diagnosis delayed by omitting biopsy<sup>3,4</sup>. These results highlight the synergistic effect of microUS and MRI for the detection of csPCa, with increase rates of detection of csPCa when utilizing a microUS biopsy, even with negative MRI.

There are several limitations of this study. This study is a retrospective, single site design. The sample size of this study was limited and only includes patients who were referred for biopsy despite negative MRI. Furthermore, the microUS group had a larger percentage of patients with PSA density  $> 0.15$  which are at a higher risk of csPCa. Further studies are necessary to better address this question, which the ongoing Optimization of Prostate Biopsy – Micro-Ultrasound versus MRI (OPTIMUM) trial may help provide<sup>14</sup>.

## CONCLUSIONS

MicroUS informed prostate biopsy could be a useful adjunct for helping detect csPCa in the setting of a negative MRI and underscores high rates of csPCa detected despite negative MRI.

## REFERENCES

1. Ahmed HU, El-Shater Bosaily A, Brown LC, et al. Diagnostic accuracy of multi-parametric MRI and TRUS biopsy in prostate cancer (PROMIS): A paired validating confirmatory study. *Lancet* 2017;389:815-22. [https://doi.org/10.1016/S0140-6736\(16\)32401-1](https://doi.org/10.1016/S0140-6736(16)32401-1)
2. Norris JM, Kinnaird A, Margolis DJ, et al. Developments in MRI-targeted prostate biopsy. *Curr Opin Urol* 2020;30:1-8. <https://doi.org/10.1097/MOU.0000000000000683>
3. Mason RJ, Marzouk K, Finelli A, et al. UPDATE - 2022 Canadian Urological Association recommendations on prostate cancer screening and early diagnosis: Endorsement of the 2021 Cancer Care Ontario guidelines on prostate multiparametric magnetic resonance imaging. *Can Urol Assoc J* 2022;16:86-7. <https://doi.org/10.5489/cuaj.7851>
4. EAU Guidelines. Edn. presented at the EAU Annual Congress Milan. Published 2023. Accessed August 22, 2023. <https://uroweb.org/guidelines/prostate-cancer/chapter/diagnostic-evaluation>
5. Kinnaird A, Sharma V, Chuang R, et al. Risk of prostate cancer after a negative magnetic resonance imaging guided biopsy. *J Urol* 2020;204:1180-6. <https://doi.org/10.1097/JU.0000000000001232>
6. Albers P, Wang B, Broomfield S, et al. Micro-ultrasound versus magnetic resonance imaging in prostate cancer active surveillance. *Eur Urol Open Sci* 2022;46:33-5. <https://doi.org/10.1016/j.euros.2022.09.019>
7. Wang B, Broomfield S, Medina Martín A, et al. Detection of clinically significant prostate cancer by micro-ultrasound-informed systematic biopsy during MRI/micro-ultrasound fusion biopsy. *Can Urol Assoc J* 2023;14:117-20. <https://doi.org/10.5489/cuaj.8094>
8. Lughezzani G, Maffei D, Saita A, et al. Diagnostic accuracy of microultrasound in patients with a suspicion of prostate cancer at magnetic resonance imaging: A single-institutional prospective study. *Eur Urol Focus* 2021;7:1019-26. <https://doi.org/10.1016/j.euf.2020.09.013>
9. Hofbauer SL, Luger F, Harland N, et al. A non-inferiority comparative analysis of micro-ultrasonography and MRI-targeted biopsy in men at risk of prostate cancer. *BJU Int* 2022;129:648-54. <https://doi.org/10.1111/bju.15635>
10. Rohrbach D, Wodlinger B, Wen J, et al. High-frequency quantitative ultrasound for imaging prostate cancer using a novel micro-ultrasound scanner. *Ultrasound Med Biol* 2018;44:1341-1354. <https://doi.org/10.1016/j.ultrasmedbio.2018.02.014>
11. Ghai S, Eure G, Fradet V, et al. Assessing cancer risk on novel 29 MHz micro-ultrasound images of the prostate: Creation of the micro-ultrasound protocol for prostate risk identification. *J Urol* 2016;196:562-9. <https://doi.org/10.1016/j.juro.2015.12.093>
12. Org S, Cash H, Hofbauer SL, et al. Prostate cancer detection by novice micro-ultrasound users enrolled in a training program. *Soc Int Urol J* 2022;3:62-8. <https://doi.org/10.48083/KKVJ7280>
13. Avolio PP, Lughezzani G, Fasulo V, et al. Assessing the role of high-resolution microultrasound among naïve patients with negative multiparametric magnetic resonance imaging and a persistently high suspicion of prostate cancer. *Eur Urol Open Sci* 2023;47:73-9. <https://doi.org/10.1016/j.euros.2022.11.015>

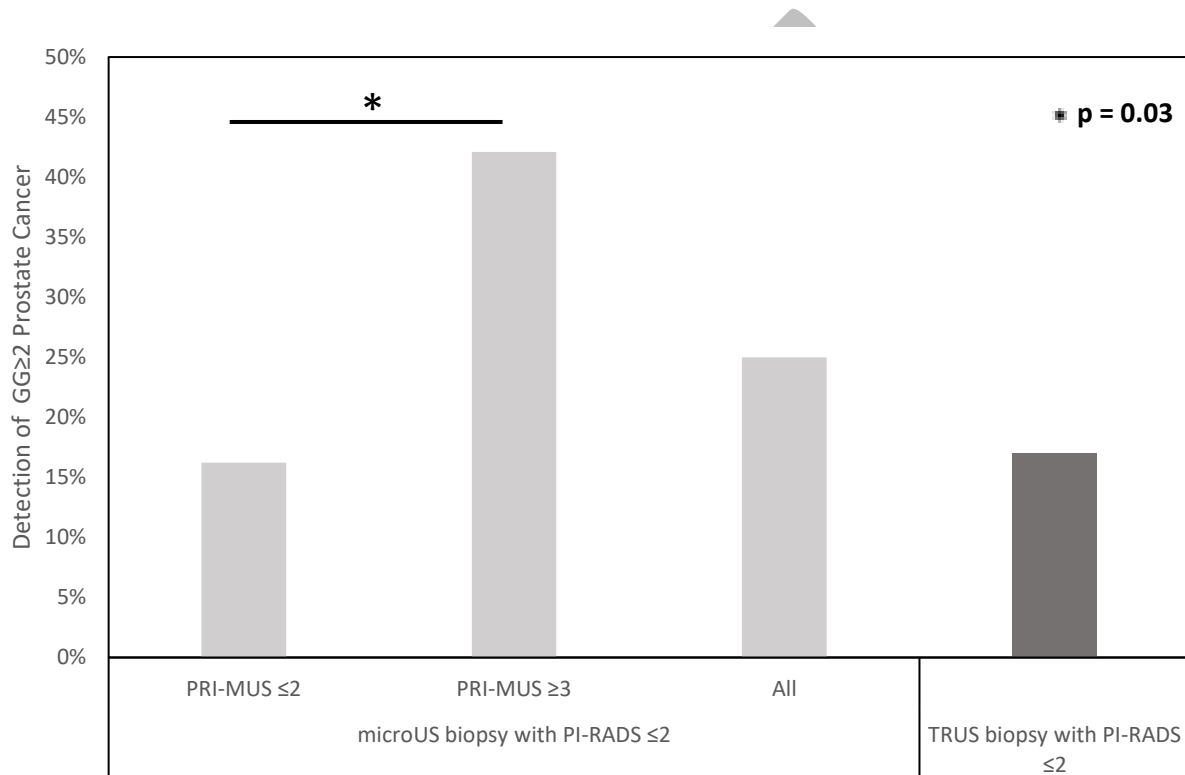
14. Klotz L, Andriole G, Cash H, et al. Optimization of prostate biopsy - Micro-Ultrasound versus MRI (OPTIMUM): A 3-arm randomized controlled trial evaluating the role of 29 MHz micro-ultrasound in guiding prostate biopsy in men with clinical suspicion of prostate cancer. *Contemp Clin Trials* 2022;112:106618.  
<https://doi.org/10.1016/j.cct.2021.106618>

*Conflicts of interest: Dr. Kinnaird has received grant funding from Exact Imaging for unrelated research studies.*

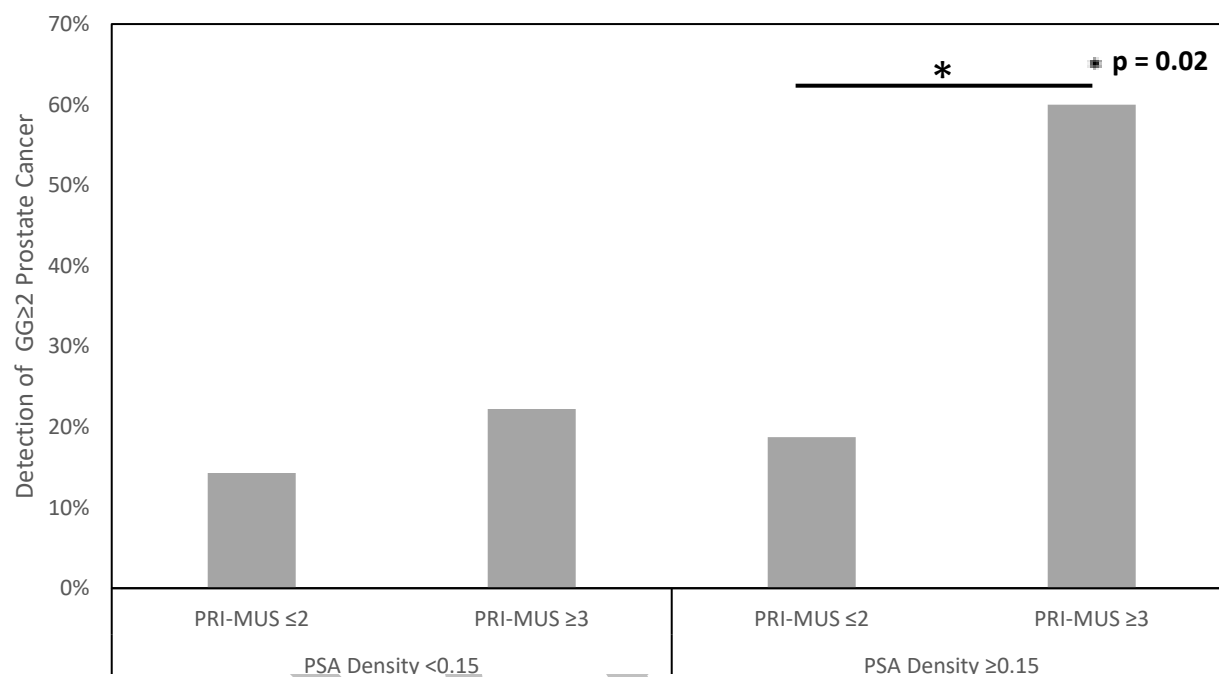
DRAFT

## FIGURES AND TABLES

**Figure 1.** Detection rates of Gleason grade group  $\geq 2$  prostate cancer for MRI-negative patients undergoing transrectal microUS or standard transrectal ultrasound biopsy. GG: Gleason grade group; microUS: micro-ultrasound; MRI: magnetic resonance imaging; PRI-MUS: prostate risk identification using micro-ultrasound score; PI-RADS v2.1: prostate imaging, reporting, and data system; TRUS: transrectal ultrasound.



**Figure 2.** Detection rates of Gleason grade group  $\geq 2$  prostate cancer for MRI-negative patients undergoing microUS biopsy stratified by PSA density and PRI-MUS score. GG: Gleason grade group; PRI-MUS: prostate risk identification using micro-ultrasound score; PSA: prostate-specific antigen.



<b>Table 1. Baseline patient, imaging, and biopsy characteristics</b>			
	<b>microUS (n=56)</b>	<b>TRUS (n=47)</b>	<b>p</b>
Age, mean (SD)	61.4 (7.2)	61.9 (7.8)	0.77
Ethnicity, (%)			0.78
Asian	8 (14)	7 (15)	
Black	2 (4)	4 (9)	
Caucasian	43 (77)	32 (68)	
Hispanic	0 (0)	0 (0)	
Indigenous	2 (4)	3 (6)	
Unknown	1 (2)	1 (2)	
Family history of prostate cancer, n (%)	16 (29)	10 (21)	0.40
Abnormal DRE, (%)	5 (9)	6 (13)	0.53
PSA (ng/mL), median (IQR)	7.3 (5.9-8.4)	6.8 (5.0-9.3)	0.33
Prostate volume (cc), median (IQR)	51.5 (38.9-68.9)	69 (50.5-82.0)	0.33
PSA density (ng/mL/cc), (%)			<b>&lt;0.01</b>
<0.15	30 (54)	39 (83)	
≥0.15	26 (46)	8 (17)	
PRI-MUS score, (%)			N/A
≤2	37 (66)		
3	4 (7)	N/A	
4	3 (5)		
5	12 (21)		

DRE digital rectal exam; IQR: interquartile range; PRI-MUS: prostate risk identification using micro-ultrasound score; PSA: prostate-specific antigen; SD: standard deviation; TRUS: transrectal ultrasound biopsy.